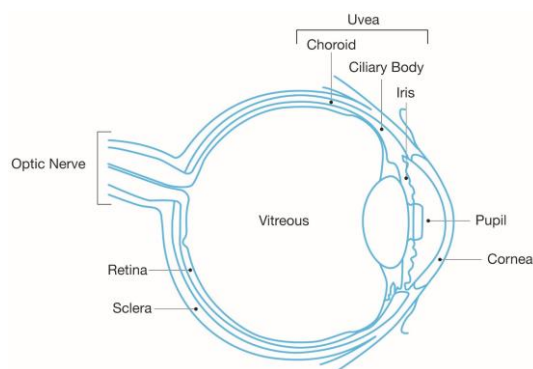


## What is Ocular Melanoma?

Ocular melanoma (OM) includes two types of cancer: Uveal melanoma, a cancer that develops in the pigmented uveal tract within the eye, and [conjunctival melanoma](#) found on the surface of the eye and more similar to skin melanoma.

There are approximately [six cases of ocular melanoma per million people per year](#). OM accounts for [3-4% of all melanomas](#).

Whilst there are similarities, ocular and cutaneous (skin) melanoma are genetically very different.



Anatomy of the human eye

## Diagnosis & Symptoms

- Ocular melanoma is often found during a dilated eye exam, and can sometimes be spotted at a routine test, yet neither of these confirm diagnosis
- Symptoms can include flashing lights, floaters and blurring of vision
- Many people with ocular melanoma do not experience any symptoms
- To confirm diagnosis patients are typically referred to a specialist centre who will perform a number of tests which often include ultrasound, colour photography and visual examination of the eye.

## Surveillance

Because spread usually occurs first in the liver, most surveillance concentrates on this area. The most accurate way to diagnose any metastatic disease is to use MRI with a contrast agent; this can see small areas of cancer to 2-3mm. In many centres this is offered 6-monthly. MRI without contrast is less sensitive and CT (computerised tomography) scans even less so, although these are also commonly used as well as ultrasound of the liver. Yearly checks of other areas of the body are common too.

## Treatments

Small and medium tumours are usually treated with radiation. This can be using [brachytherapy](#), where a convex disk is attached to the outside the eye and left for a few days to irradiate the tumour, or using [proton beam therapy](#) which focuses a beam of energy at the tumour to kill it. For larger tumours [enucleation](#) (removal of the eye) is often performed, and rarely [exenteration](#).

It is important to obtain treatment at a specialist centre that deals with ocular melanoma. Note that specialist centres treating the eye are often different from those [treating metastatic \(spread\) disease](#).

For those with metastatic spread there are a number of liver-directed treatments, including [chemosaturation](#), [SIRT](#), [TACE](#), [ablation](#) and [stereotactic radiation](#) as well as [resection](#) (cutting out the tumour) available at specialist centres in Europe. New systemic (whole body) treatments, including [immunotherapy](#) and [targeted genetic](#) options have also shown promise.

## Thank You

We are very grateful to [OcuMel UK](#), the [Melanoma Research Foundation](#), [The Eye Cancer Foundation](#), [The THANC Foundation](#) and the [Ocular Melanoma Foundation](#) for the use of their material where appropriate. Thank you all for your input!

## Further Reading

Clinical trials: <https://clinicaltrials.gov/>

Uveal melanoma in Wikipedia

[https://en.wikipedia.org/wiki/Uveal\\_melanoma](https://en.wikipedia.org/wiki/Uveal_melanoma)

More advanced material:

<http://onlinelibrary.wiley.com/doi/10.1111/pcmr.12304/pdf>

To the best of our knowledge this document is correct and up-to-date. Should you find inaccuracies please contact:

[mpneocular@idcapture.co.uk](mailto:mpneocular@idcapture.co.uk)

## Genetic Testing

Ocular melanoma spreads, usually to the liver, in [about 50% of cases](#). Genetic testing helps determine this risk and is offered in many ocular oncology centres. A tumour sample is examined and, while [not 100% accurate](#), gives an indication of the likelihood of future spread. [3-4% are diagnosed with metastases \(spread\) at the time of initial diagnosis](#).